

Tracheal surgery in Germany

Dominik Herrmann¹, Jan Volmerig¹, Melanie Oggiano¹, Santiago Ewig², Erich Hecker¹

¹Thoraxzentrum Ruhrgebiet, Department of Thoracic Surgery, Evangelisches Krankenhaus, Herne, Germany; ²Thoraxzentrum Ruhrgebiet, Department of Respiratory and Infectious Diseases, Evangelisches Krankenhaus, Herne, Germany

Contributions: (I) Conception and design: E Hecker, J Volmerig, D Herrmann; (II) Administrative support: E Hecker; (III) Provision of study materials or patients: None; (IV) Collection and assembly of data: D Herrmann, E Hecker; (V) Data analysis and interpretation: D Herrmann, M Oggiano; (VI) Manuscript writing: All authors; (VII) Final approval of manuscript: All authors.

Correspondence to: Erich Hecker. Thoraxzentrum Ruhrgebiet, Department of Thoracic Surgery, Evangelisches Krankenhaus, Hordeler Straße 7-9, 44651 Herne, Germany. Email: e.hecker@evk-herne.de.

Abstract: First attempts of tracheal surgery in Germany were made in 1881 and tracheal resection was performed in dogs. First experiences in tracheal for malignant tracheal stenosis with tracheal resection and end-to-end anastomosis in humans were published in 1915 by the same surgeons. In 20th century several techniques of tracheal mobilisation and coverage of the anastomosis were developed to enable sufficient end-to-end anastomosis. Uniportal thoracoscopic techniques and extracorporeal membrane oxygenation are progresses established more or less recently in the last decade. We performed a literature research in PubMed concerning tracheal surgery and evaluated data from the “Federal Statistical Office Germany”. In the later we requested extraction of data from the German diagnosis-related-groups (G-DRG)-system database concerning procedures and diagnoses affecting tracheal resection and management of tracheal injury. In 2018 in Germany, 267 patients were treated for neoplasm of the trachea and 66 patients for tracheal injury of the pars thoracica. Acquired tracheal stenosis was diagnosed in 1070 patients and tracheal stenosis after medical intervention in 740 individuals. There was no distinct difference in the number of cases of these diagnoses between 2014 and 2018. The most common tracheal operation in Germany is the closure of tracheostoma, which was performed almost 5000 times per year between 2014 and 2018. Treatment of tracheal stenosis was mainly bronchoscopic. Most frequent method was the dilatation of the stenosis without implantation of a stent in 314 cases, followed by bronchoscopic excision of tissue in 119 patients. Surgical management consisted of resection of tracheal stenosis with end-to-end anastomosis in 72 cases in 2018. Management of tracheal neoplasm was with multimodal predominantly. The management of tracheal diseases is predominately performed by bronchoscopic procedures. This affects the diagnostic procedures, as well as the therapeutic interventions. It is conspicuous that there is a lack between the number of encoded diagnoses in every field of tracheal diseases and the number of encoded diagnostic and therapeutic procedures. The reason for this circumstance is unclear.

Keywords: Tracheal surgery; tracheal resection; tracheal laceration; tracheal injury

Received: 28 November 2019; Accepted: 04 December 2019.

doi: 10.21037/ccts.2019.12.02

View this article at: <http://dx.doi.org/10.21037/ccts.2019.12.02>

Introduction

First published literature concerning tracheal surgery in Germany was presented in 1881 by Themistokles Gluck. He demonstrated the feasibility of tracheal resection and end-to-end anastomosis in dogs for the first time (1). Few years later, in 1915, Gluck and his colleague Johannes Soerensen

published a first description of tracheal resection and airway reconstruction in humans (2), describing the cases of two individuals with malignant stenosis of the trachea. In both patients, tracheal sleeve resection was performed, a R0 margin was achieved and a 24-month follow-up showed no recurrence.

The challenging problem in tracheal surgery with end-to-end-anastomosis is reduction of tension at the anastomosis to allow a sufficient healing. During the 20th century, several surgeons developed approaches to improve tracheal mobilisation enabling extended resection without intense tension at the anastomosis.

During the same period, multiple techniques of covering the anastomosis with tissue flaps were developed (3) and especially the work of Hermes C. Grillo was a landmark in progress of tracheal surgery. Grillo and colleagues presented a new technique, allowing to resect half of the trachea and still facilitating a sufficient end-to-end anastomosis (4).

The increasing use of extracorporeal membrane oxygenation is one of the latest innovations providing full respiratory support in tracheal surgery (5).

Another recent development is the progress of minimal invasive surgery. These techniques also affect the field of tracheal surgery including tracheal resection and reconstruction by mediastinoscopic approach (6) as well as video-assisted thoracoscopic surgery (VATS) (7). The first circumferential resection and primary end-to-end anastomosis of the trachea, operated via VATS, was already published by Nakanishi in 2005 (8) and several surgeons adopted and enhanced this approach, up to the latest reports of carinal sleeve resection carried out by uniportal VATS.

The work of Jianxing He and colleagues needs to be highlighted in this field. They published multiple case reports and case series evidently revealing the progress of advanced thoracic surgery. These contributions illustrate the evolution from resection of a tracheal mass with three-port-VATS under non-intubated anaesthesia (9), followed by VATS with carinal reconstruction (10), to uniportal VATS for tracheal resection in a spontaneous breathing patient (11). Certainly, it must be mentioned that uniportal non-intubated VATS is not the standard approach for tracheal surgery in German departments for thoracic surgery.

Methods

We performed a literature research in PubMed concerning tracheal surgery and evaluated data from “Federal Statistical Office Germany”. In the later we requested extraction of data from German diagnosis-related-groups (G-DRG)-system database concerning procedures and diagnoses affecting tracheal resection and management of tracheal injury.

The exact amount of each procedure is diagrammed in case of more than 3 procedures per year, otherwise the number is presented as “below 3” (<3). The Number of

deceased patients related to a diagnosis or the treatment is not directly related to the intervention, but records death during the same hospitalisation period as encoded in G-DRG.

Tracheal resection

Certainly, primary neoplasms of the trachea are rare, most common entities being squamous cell carcinoma and adenoid cystic carcinoma. More often neoplasms of the trachea are secondary and the initial tumours origin from the esophagus, thyroid gland or the lung (12).

Therefore the most important indication for tracheal resection is tracheal stenosis, due to iatrogenic reasons like tracheostomy or cuff-induced after prolonged mechanical ventilation. Other forms of tracheal stenosis are idiopathic or secondary caused by compression, sarcoidosis, amyloidosis, granulomatosis with polyangitis or tracheopathia osteochondroplastica (13).

Signs and symptoms may vary in every patient, because the individual might be adopted to respiratory insufficiency after a slow process of the disease. On the other hand some patients show notable signs like dyspnea or stridor and the situation might be life-threatening. First obvious signs often appear only after tracheal restriction of more than 50%.

In every tracheal disease or injury the bronchoscopic evaluation is the most important diagnostic tool leading to exact diagnosis and management decision. Other methods, like body plethysmography or radiologic procedures can help to identify the severity of the disease, but only bronchoscopy is able to show the extent of a tracheal mass, injury or stenosis (13).

For the treatment of a tracheal mass several methods are available. The tumor might be resected via rigid fiber optic bronchoscopy, a restriction might be dilatated with a bougie, stent implantation can be performed and in some cases there is the indication for surgical approach (14).

The keystone of every resection of the trachea is to avoid tension on the end-to-end anastomosis. This is independent of the surgical approach being cervical, transsternal or via thoracotomy. It is independent from surgeon's experience and from patient's characteristics. Tension on the anastomosis can lead to insufficiency, bleeding, infections and re-stenosis, so it needs to be avoided (15).

In the most cases of tracheal stenosis the tracheal segment which needs to be resected comprises 2–4 cm and is located in the cervical part due to tracheostomy or prolonged mechanical ventilation. The surgical approach is cervical in these cases and mobilisation of the trachea is

necessary just for 1 cm to both sides of the resected part. Further mobilisation can lead to injury of surrounded organs or impairment of tracheal perfusion (13).

Especially during percutaneous dilatational tracheostomy an injury of the cricoid cartilage may occur. In these cases a challenging subglottic cricotracheal reconstruction may be indicated. Nevertheless, even in specialized centers for thoracic surgery tracheal resection remains to be one of the most challenging procedures (16).

Tracheal injury

Tracheal injury is basically classified in two forms, based on the mechanism of laceration. First is the iatrogenic tracheal laceration as a rare, but life-threatening complication of endobronchial intubation. The other one is a traumatic tracheal lesion following blunt chest trauma or penetration.

The incidence of tracheal injury after endotracheal intubation, dependant on the manner of intubation is approximately 0.005% in a single-lumen intubation, 0.05–0.19% in a double-lumen intubation and 0.2–0.7% after percutaneous dilatational tracheostomy (17).

Subcutaneous or mediastinal emphysema, dyspnea and hemoptysis are typical signs and symptoms of tracheal injury and may occur delayed. Nevertheless, clinically apparent injuries are often life threatening and patients are in need of rapid and experienced evaluation and treatment, as iatrogenic tracheal laceration is a complication accompanied with a high mortality, stated with up to 42% (18). Reasons for the high mortality are alleged to be the underlying diseases, which led to intubation. Multiple organ dysfunction syndrome is one the most important causes of death in perioperative management for iatrogenic tracheal laceration.

Unfortunately, criteria of decision-making for treatment are inconsistent and vary from conservative management to surgery dependant on clinical status, necessity of further mechanical ventilation and depth of the lesion (17).

In stable patients without need of mechanical ventilation, conservative management is an appropriate treatment and stenting of the trachea is a common procedure. In patients with transmural injury or necessity of mechanical ventilation surgical management of iatrogenic tracheal lesions is still the gold standard of treatment (19). One important disadvantage of conservative management is the development of a tracheal instability without surgical intervention (20).

In 1995 Angelillo-Mackinlay published first results of a transcervical approach for surgical treatment of tracheal

laceration (21). This approach enables the management of lesions down to the carina. Lacerations of the main bronchus are reached via thoracotomy (22). Aim of transcervical approach is the reduction of mortality by avoiding necessity of thoracotomy and causing less trauma in these patients.

The mechanism of tracheal injury after blunt thoracic trauma is either thoracic compression in combination with glottis closure or sudden high-speed deceleration trauma. In contrast to iatrogenic tracheal tear, with longitudinal injury of the pars membranaceous, in these cases injury mostly occurs as disrapture of the trachea or mainstem bronchus.

Tracheobronchial avulsion resulting from blunt trauma is a rare but serious condition. Blunt chest trauma represent just 3% of all tracheobronchial injuries, but prehospital mortality is up to 80%. In most cases the intrathoracic tracheobronchial tree is involved. In contrast, cervical trachea is commonly affected in case of stab or gunshot wounds (23).

Signs and symptoms vary from asymptomatic patients up to rapid drop in O₂ saturation and acute respiratory insufficiency as a life-threatening situation. Common signs and symptoms are dyspnea, subcutaneous or mediastinal emphysema and pneumothorax (23).

In most cases surgical management is mandatory. Surgical approach depends on site of the injury and transcervical approach, thoracotomy or sternotomy are standard approaches. In disrapture of the tracheobronchial tree after blunt chest trauma a tracheal or bronchial resection with end-to-end anastomosis is advisable. Tracheal injury due to penetration usually requires surgical management in form of debridement and primary suture.

Potential consequence of an undiagnosed tracheal injury in initial asymptomatic patient is the development of tracheal stenosis, possibly demanding further intervention (13).

Results

The Federal Statistical Office Germany extracted data of the G-DRG system related to the following main diagnoses:

- ❖ Neoplasm of the trachea; n=367 in 2018;
- ❖ Injury of the neck, not further described; n=24 in 2018;
- ❖ Injury of the trachea, pars thoracica; n=66 in 2018;
- ❖ Acquired tracheal stenosis; n=1,070 in 2018;
- ❖ Disease of upper airway, not further described; n=287 in 2018;
- ❖ Tracheal stenosis after medical intervention; n=740 in 2018;
- ❖ Congenital malformation of the trachea; n=83 in

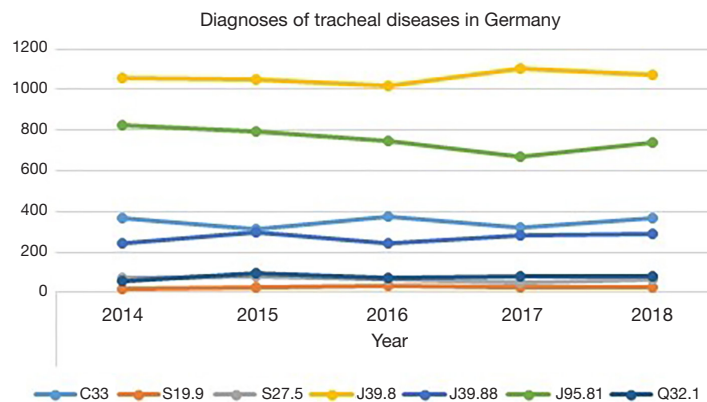


Figure 1 Number of tracheal diseases encoded in G-DRG system. C33: neoplasm of the trachea; S19.9: injury of the neck, not further described; S27.5: injury of the trachea, pars thoracica; J39.8: acquired tracheal stenosis; J39.88: disease of upper airway, not further described; J95.81: tracheal stenosis after medical intervention; Q32.1: congenital malformation of the trachea.

2018.

The number of diagnosis and the development between 2014 and 2018 is shown in *Figure 1*.

The most common tracheal operation in Germany is the surgical closure of a tracheostoma, which was performed almost 5000 times per year between 2014 and 2018. The mortality of these patients at the same hospitalisation period was 1% (*Table 1*). Other procedures in tracheal surgery in Germany and the number of deceased patients is given in *Table 1*. It is shown that most interventions at the trachea are bronchoscopic, like dilatation with or without implantation of a stent or excision of malignant tissue. In surgical management, open surgery is the usual approach compared to VATS, as mentioned introductory.

Tracheal dilatation with or without implantation of a stent is performed for tracheal stenosis or tracheal neoplasm and is one of the most common procedures in treatment of tracheal diseases in Germany (*Table 1*, *Figure 2*).

Tracheal injury

In 2018, 66 patients with tracheal injury were treated in Germany (*Figure 1*). In 40 of these patients bronchoscopic evaluation was performed. In 10 more cases bronchoscopy was supplemented by bronchoalveolar lavage. Rigid bronchoscopy for evaluation of tracheal injury was performed less than three times.

Fourteen patients underwent computed tomography (CT) with contrast of the neck and four patients CT without contrast of the neck. Chest-CT with contrast was conducted in 27 cases. Thirteen patients received chest-CT

without contrast.

Primary suture of the laceration was performed in 32 cases. Eight patients received a temporary tracheostomy and in six individuals the tracheostomy was permanent. In 2018, 11 of the 66 patients with tracheal injury underwent a cardiopulmonary resuscitation.

The analysis of data of procedures performed in Germany in 2018 shows 6 cases with tracheal resection with end-to-end anastomosis after blunt injury and 189 procedures with reconstruction after tracheal injury. Unfortunately these data do not differentiate mechanism of injury and probably procedures due to accidental intraoperative injury are included.

Tracheal neoplasm

Three hundred and sixty-seven patients with tracheal neoplasm were treated in Germany in 2018 (*Figure 1*).

One hundred and sixty-eight patients underwent flexible bronchoscopy and in 65 cases bronchoscopy was performed in rigid technique. Chest-CT with contrast was conducted in 106 individuals and CT with three-dimensional analysis was performed in 50 patients.

In 72 cases the histopathologic evaluation of tracheal neoplasm for performed by bronchoscopic incision of the trachea and in 29 patients by bronchoscopic incision of a bronchus.

Management of tracheal neoplasm was predominantly multimodal. Surgical resection, bronchoscopic destruction of malignant tissue, radiotherapy and chemotherapy were performed in more than 20 cases each (*Table 2*).

Table 1 Procedures in tracheal surgery in Germany

Procedure	2018	2017	2016	2015	2014
Excision of tracheal tissue, open surgery	252	258	276	282	207
Deceased patients	9	11	9	12	9
Excision of tracheal tissue, thorascopic	6	16	12	11	5
Deceased patients	0	0	0	0	0
Excision of tracheal tissue, bronchoscopic	632	636	609	533	541
Deceased patients	24	16	13	14	22
Tracheal resection with end-to-end anastomosis	124	162	148	154	146
Deceased patients	7	8	4	6	6
Tracheal resection with tracheostomy	124	172	167	161	174
Deceased patients	12	22	19	20	19
Reconstruction after tracheal injury	178	189	149	179	189
Deceased patients	33	40	28	26	35
Destruction of malignant tissue in trachea, open surgery	46	46	40	40	36
Deceased patients	5	0	0	0	0
Destruction of malignant tissue in trachea, bronchoscopic	464	508	435	436	548
Deceased patients	25	25	21	23	31
Closure of a tracheostomy	4964	4879	4997	4976	4823
Deceased patients	54	46	37	44	48
Resection of tracheal stenosis with end-to-end anastomosis	46	70	66	67	75
Deceased patients	0	4	0	3	0
Resection of tracheal stenosis, other	190	180	199	233	166
Deceased patients	4	3	5	3	3
Treatment of tracheal stenosis with stent	100	108	127	149	130
Deceased patients	11	10	13	9	11
Tracheal dilatation without stent implantation	759	664	656	582	585
Deceased patients	35	25	24	28	30
Tracheal dilatation with hybrid stent	199	156	165	184	170
Deceased patients	37	27	32	29	35
Tracheal dilatation with synthetic stent	140	205	182	201	180
Deceased patients	14	21	12	16	19
Tracheal dilatation with metal stent	214	271	257	257	254
Deceased patients	39	53	30	41	31
Carinal resection	19	13	19	18	11
Deceased patients	5	0	3	4	0

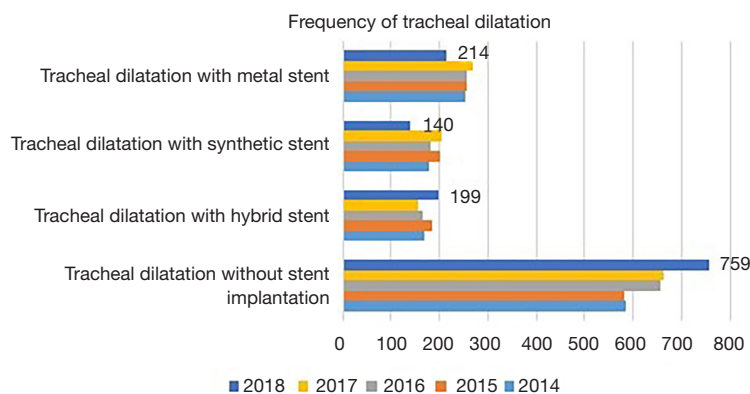


Figure 2 Frequency of tracheal dilatation with and without implantation of a stent between 2014 and 2018 in Germany.

Table 2 Procedures performed in patients with diagnosis neoplasm of the trachea

Procedure	2018 (n=367)	2017 (n=319)	2016 (n=375)	2015 (n=311)	2014 (n=366)
Flexible bronchoscopy	168	125	165	152	168
Rigid bronchoscopy	65	57	70	75	76
Endoscopic incision, trachea	72	68	82	56	65
Endoscopic incision, bronchus	29	20	30	27	26
Body plethysmography	102	94	111	83	97
CT of the neck without contrast	9	9	4	9	7
Chest CT without contrast	19	22	25	24	15
CT of the neck with contrast	46	40	35	31	33
Chest CT with contrast	106	98	118	81	99
Head CT without contrast	14	8	8	8	15
Head CT with contrast	14	22	20	21	31
Head MRI without contrast	9	5	15	4	6
Head MRI with contrast	26	17	28	21	23
3-dimensional CT analysis	50	42	35	33	21
Resection of tracheal tissue, open	4	5	4	4	3
Resection of tracheal tissue, bronchoscopy	20	28	19	15	25
Resection with end-to-end anastomosis	13	9	9	12	12
Resection with tracheotomy	<3	<3	5	3	4
Resection, other	3	3	3	4	3
Endoscopic dilatation without stent implantation	12	5	11	10	18
Endoscopic dilatation with stent implantation, hybrid	4	<3	5	5	8
Endoscopic dilatation with stent implantation, synthetic	<3	<3	6	3	<3
Endoscopic dilatation with stent implantation, metal	9	8	12	8	9
Destruction of tissue, bronchoscopic	21	24	31	15	19
Destruction of tissue, cryo-biopsy	9	10	10	14	12

<3, less than three times; CT, computed tomography.

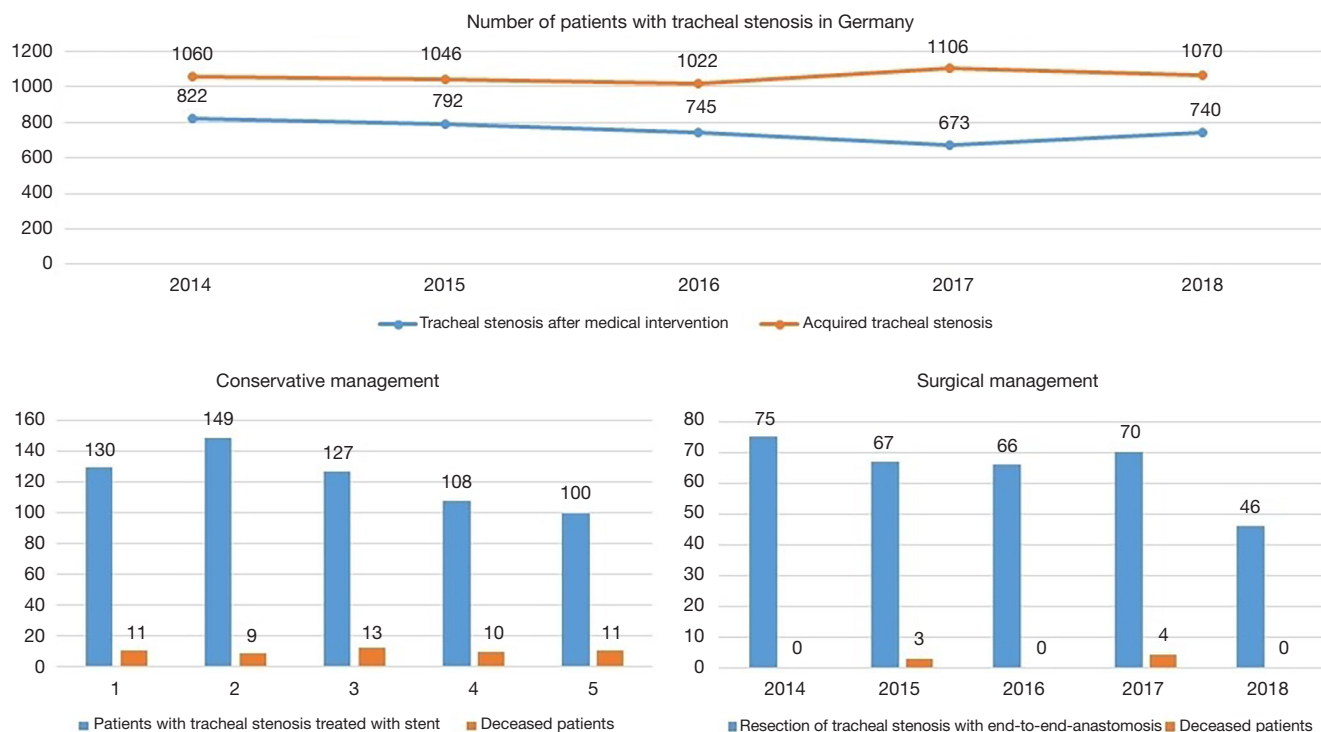


Figure 3 Number of patients with tracheal stenosis and management decision. Surgical management is focused on resection with end-to-end anastomosis.

Tracheal stenosis

The underlying ICD-10-GM to the G-DRG differentiates two codes for tracheal stenosis. First one is the “acquired tracheal stenosis” (ATS), the other one is the “tracheal stenosis following medical intervention” (TSMI). The number of cases is shown in *Figures 1,3*.

Clinical diagnostics are based on bronchoscopic evaluation. Flexible bronchoscopy was performed 582 times in 2018 for ATS and 359 times for TSMI. Additional bronchoscopic evaluation in rigid technique took place 288 cases in 2018 for ATS and in 218 cases for TSMI. In 2018, chest-CT with contrast was performed 154 times and 77 times without contrast for ATS. Patients with TSMI received chest-CT with contrast 66 times and in 47 times without contrast.

The preferred management was conservative, as shown in *Figure 3*. Most common method was the dilatation of the stenosis without implantation of a stent (203 cases in 2018 for ATS and 111 cases in 2018 for TSMI), followed by bronchoscopic excision of tissue in 71 patients in 2018

for ATS and in 48 patients in 2018 for TSMI. Surgical management consisted of resection of tracheal stenosis with end-to-end anastomosis in 20 cases in 2018 for ATS and 52 cases for TSMI. Additional information of encoded procedures related to patients with tracheal stenosis between 2014 and 2018 is shown in *Table 3* for ATS and *Table 4* for TSMI.

Conclusions

Management of tracheal diseases is predominately performed by bronchoscopic procedures. This affects diagnostic procedures as well as therapeutic interventions. It is conspicuous that there is a lack between the number of encoded diagnoses in every field of tracheal diseases and the number of encoded diagnostic and therapeutic procedures. Explanations might be incorrect encoding by physicians or redundant treatment in asymptomatic or palliative patients. The data of the Federal Statistical Office Germany doesn't provide sufficient answer to this question.

Table 3 Procedures performed in patients with diagnosis of acquired tracheal stenosis

Procedure	2018 (n=1,070)	2017 (n=1,106)	2016 (n=1,022)	2015 (n=1,046)	2014 (n=1,060)
Diagnostic laryngoscopy	266	236	218	245	224
Flexible bronchoscopy	582	614	516	512	540
Flexible bronchoscopy with bronchoalveolar lavage	89	76	83	91	68
Flexible bronchoscopy, other	93	106	107	104	128
Rigid bronchoscopy	288	346	n.a.	342	310
Rigid bronchoscopy, other	18	16	n.a.	19	13
Body plethysmography	85	81	89	89	83
CT of the neck without contrast	60	66	46	57	67
Chest CT without contrast	77	98	69	80	98
CT of the neck with contrast	106	121	98	113	107
Chest CT with contrast	154	158	141	159	139
3-dimensional CT analysis	117	129	91	99	89
Excision of tissue, open surgery	13	7	8	22	10
Excision of tissue, bronchoscopic	71	65	68	58	44
Resection with end-to-end anastomosis	20	43	30	33	35
Resection with tracheotomy	8	6	4	<3	<3
Resection, other	4	6	5	<3	6
Destruction of tissue, bronchoscopic	51	59	45	49	97
Destruction of tissue, other	11	9	6	9	4
Endoscopic dilatation without stent implantation	203	167	159	165	138
Endoscopic dilatation with stent implantation, hybrid	32	19	13	25	14
Endoscopic dilatation with stent implantation, synthetic	27	45	37	43	33
Endoscopic dilatation with stent implantation, metal	17	37	32	36	35
Resuscitation	14	13	15	11	13

n.a., not available; <3, less than three times; CT, computed tomography.

Table 4 Procedures performed in patients with diagnosis of tracheal stenosis following medical intervention

Procedure	2018 (n=740)	2017 (n=673)	2016 (n=749)	2015 (n=792)	2014 (n=822)
Diagnostic laryngoscopy	134	121	154	115	158
Diagnostic pharyngoscopy	56	44	65	44	47
Flexible bronchoscopy	359	335	360	401	346
Flexible bronchoscopy with bronchoalveolar lavage	42	32	45	44	40
Flexible bronchoscopy, other	67	51	56	66	72
Rigid bronchoscopy	218	199	249	237	262
Rigid bronchoscopy, other	37	32	59	58	72
Body plethysmography	166	166	173	181	185
CT of the neck without contrast	40	33	32	38	36
Chest CT without contrast	47	42	41	43	52
CT of the neck with contrast	52	47	51	48	56
Chest CT with contrast	66	56	49	68	66
3-dimensional CT analysis	57	49	43	48	56
Excision of tissue, open surgery	10	9	14	11	15
Excision of tissue, bronchoscopic	48	41	43	45	44
Resection with end-to-end anastomosis	52	47	46	52	44
Resection with tracheotomy	5	3	<3	3	5
Resection, other	3	<3	9	13	5
Destruction of tissue, Bronchoscopic	43	62	53	51	54
Management of tracheal stenosis with end-to-end anastomosis	13	24	17	19	23
Management of tracheal stenosis with stent	20	21	25	26	33
Management of tracheal stenosis, other	35	25	45	45	36
Endoscopic dilatation without stent implantation	111	90	99	79	82
Endoscopic dilatation with stent implantation, hybrid	3	4	10	<3	8
Endoscopic dilatation with stent implantation, synthetic	25	24	20	34	28
Endoscopic dilatation with stent implantation, metal	10	11	10	8	10

<3, less than three times; CT, computed tomography.

Acknowledgments

None.

Footnotes

Conflict of Interest: The authors have no conflicts of interest to declare.

Ethical Statement: the authors are accountable for all

aspects of the work in ensuring that questions related to the accuracy or integrity of any part of the work are appropriately investigated and resolved.

References

1. Gluck T, Zeller A. Die prophylaktische Resektion der Trachea. Arch Klin Chir 1881;26:427-36.
2. Soerensen J. Zwei Fälle von Totalexstirpation der Trachea wegen Karzinom. Archiv Laryngol Rhinol

- 1915;29:188-204.
3. Grillo HC. Development of tracheal surgery:a historical review. Part 1: Techniques of tracheal surgery. *Ann Thorac Surg* 2003;75:610-9.
4. Grillo HC, Dignan EF, Miura T. Extensive resection and reconstruction of mediastinal trachea without prosthesis or graft: an anatomical study in man. *J Thorac Cardiovasc Surg* 1964;48:741-9.
5. Rinieri P, Peillon C, Bessou JP, et al. National review of use of extracorporeal membrane oxygenation as respiratory support in thoracic surgery excluding lung transplantation. *Eur J Cardiothorac Surg* 2015;47:87-94
6. Herrmann D, Schoch M, Hecker E. Videomediastinoskopische Tracheateilresektion und Rekonstruktion. *Zentralbl Chir* 2017;142:S67-S112.
7. Gonzalez-Rivas D, Yang Y, Stupnik T, et al. Uniportal video-assisted thoracoscopic bronchovascular, tracheal and carinal sleeve resections†. *Eur J Cardiothorac Surg* 2016;49 Suppl 1:i6-16.
8. Nakanishi K, Kuruma T. Video-assisted thoracic tracheoplasty for adenoid cystic carcinoma of the mediastinal trachea. *Surgery* 2005;137:250-2
9. Li S, Liu J, He J, et al. Video-assisted transthoracic surgery resection of a tracheal mass and reconstruction of trachea under non-intubated anesthesia with spontaneous breathing. *J Thorac Dis* 2016;8:575-85.
10. He J, Wang W, Li J, et al. Video-assisted thoracoscopic surgery tracheal resection and carinal reconstruction for tracheal adenoid cystic carcinoma. *J Thorac Dis* 2016;8:198-203.
11. Guo M, Peng G, Wei B, et al. Uniportal video-assisted thoracoscopic surgery in tracheal tumour under spontaneous ventilation anaesthesia. *Eur J Cardiothorac Surg* 2017;52:392-4.
12. Behringer D, Könnemann S, Hecker E. Treatment Approaches to Primary Tracheal Cancer. *Thorac Surg Clin* 2014;24:73-6.
13. Volmerig J, Hecker E. Chirurgie der Trachea – Tracheal Surgery. *Zentralbl Chir* 2017;142:320-9.
14. Bolliger CT, Sutedja TG, Strausz J et al. Therapeutic bronchoscopy with immediate effect: laser, electrocautery, argon plasma coagulation and stents. *Eur Respir J* 2006;27:1258-71.
15. Wright CD, Grillo HC, Wain JC et al. Anastomotic complications after tracheal resection: prognostic factors and management. *J Thorac Cardiovasc Surg* 2004;128:731-9.
16. Porhanov VA, Poliakov IS, Selvaschuk AP, et al. Indications and results of sleeve carinal resection. *Eur J Cardiothorac Surg* 2002;22:685-94.
17. Herrmann D, Volmerig J, Al-Turki A, et al. Does less surgical trauma result in better outcome in management of iatrogenic tracheobronchial laceration? *J Thorac Dis* 2019;11:4772-81.
18. Hofmann HS, Rettig G, Radke J, et al. Iatrogenic ruptures of the tracheobronchial tree. *Eur J Cardiothorac Surg* 2002;21:649-52.
19. Cassada DC, Munyikwa MP, Moniz MP, et al. Acute injuries of the trachea and major bronchi:importance of early diagnosis. *Ann Thorac Surg* 2000;69:1563-7.
20. Welter S. Repair of tracheobronchial injuries. *Thorac Surg Clin* 2014;24:41-50.
21. Angelillo-Mackinlay T. Transcervical Repair of Distal Membranous Tracheal Laceration. *Ann Thorac Surg* 1995;59:531-2.
22. Grewal HS, Dangayach NS, Ahmad U, et al. Treatment of tracheobronchial injuries:a contemporary review. *Chest* 2019;155:595-604.
23. Symbas PN, Justicz AG, Ricketts RR. Rupture of the airways from blunt trauma:treatment of complex injuries. *Ann Thorac Surg* 1992;54:177-83.

doi: 10.21037/ccts.2019.12.02

Cite this article as: Herrmann D, Volmerig J, Oggiano M, Ewig S, Hecker E. Tracheal surgery in Germany. *Curr Chall Thorac Surg* 2019.